

Correction of Class II Malocclusion in a Late Adolescent Patient with Forsus™ (FRD) Appliance

www.adum.edu.my

Ann Dent UM 2019, 26: 34-41
Doi: 10.22452/adum.vol26no6

Mohd Zambri Mohamed Makhbul¹, Wan Nurazreena Wan Hassan^{2*}

KEYWORDS

Fixed functional appliance; Class II Division I malocclusion; Non-compliance device

ABSTRACT

Fixed functional appliances are non-compliance dependent devices, which can assist the correction of Class II malocclusion. The mechanics of the fixed functional appliances may vary depending on the type of device used. We report the observed biomechanical effects of using the Forsus™ Fatigue Resistant Device (FRD) fixed functional appliance. The patient was a 14-year-old female presented with a Class II division I malocclusion on a Class II skeletal base. The malocclusion was complicated by a 10mm overjet and increased traumatic overbite. She was treated with the Forsus™ FRD appliance worn for 5 months after the alignment with fixed appliances (0.022" X0.028" MBT prescriptions) and finished on a non-extraction base. Dento-alveolar changes were the main contribution to the correction of the malocclusion and simultaneously improved the patient's profile in the end of treatment. In conclusion, Forsus™ FRD appliance can be suggested to effectively correct Class II malocclusion.

INTRODUCTION

Class II malocclusion is a type of malocclusion, which contributes a major reason for the patient to seek for orthodontic treatment. Class II division 1 malocclusion can be attributed either by maxillary prognathism on a normal mandibular base or mandibular retrusion on a normal maxillary base or a combination of both maxillary prognathism and mandibular retrusion. The options of the treatment depend on the age of the patient, compliance and the severity of the skeletal involvement. The most common cause is contributed by mandibular

retrognathism, which is one third of the population [1]. There are several treatment options to treat Class II malocclusion, which includes camouflage orthodontic treatment, orthognathic surgery in adult patient and functional jaw orthopaedic with mandibular advancement in a growing patient [2]. Functional jaw orthopedics with mandibular advancement can be categorised into fixed functional appliances and removable functional appliances. The main advantages for using fixed functional appliances are it requires minimal patient compliance compared to removable functional appliances and it can be used concurrently with fixed appliances. The Herbst appliance, mandibular anterior repositioning appliance (MARA), Jasper Jumper and Eureka Spring are fixed functional appliances, which can be used to manage non-compliant patients with Class II malocclusion [3].

Forsus™, is a semi-rigid fixed functional appliance for Class II correction that incorporates a stainless steel

¹Orthodontic Unit, Klinik Pergigian Cahaya Suria (Sementara), Tingkat 1, Bangunan Pudu Sentral, Jalan Pudu, 50100 Kuala Lumpur, Malaysia.

²Department of Paediatric Dentistry and Orthodontics & Clinical Craniofacial Dentistry Research Group, Faculty of Dentistry, University of Malaya, 50603 Kuala Lumpur, Malaysia.

*Correspondence: wannurazreena@um.edu.my

coil spring on each side of the jaws attached to the upper molar headgear tube and a rigid stainless steel lower archwire distal to either the lower canine or lower first premolar brackets. It was developed using a unique coaxial spring design that has been claimed to be able to maintain consistent force delivery during treatment, thus called as a Fatigue-Resistant Device (FRD) [4]. The bilateral springs are compressed during activation of the appliance, which transmit consistent forces to the upper molars and the lower arches during the spring force unloading.

According to Franchi et al. [5], the Forsus™ FRD is effective in correcting Class II malocclusion with a combination of skeletal (mainly maxillary) and dento-alveolar (mainly mandibular) modifications. However, according to Aras et al. [6], this device did not appear to cause significant increases in mandibular dimensions in subjects in late puberty. The effects of the mandible were mainly at the dento-alveolar level with a large amount of mesial movement of the lower incisors and first molars [5]. In addition, in the late adolescents, there were no significant changes observed in mandibular dimensions and the dental changes were found to be practically the same in adolescents at the peak of puberty and in late puberty [6].

Past studies have discussed the effect of this appliance on skeletal and dento-alveolar changes that is relevant to sagittal correction Class II malocclusion [5, 6]. However, the biomechanical effects in other key directions of this appliance have not been described in the literature. This paper reports the correction of Class II malocclusion in a late adolescent patient using the Forsus™ fatigue resistant device (Forsus™; 3M Unitek™, Monrovia, CA, USA) and discusses the biomechanical effects of this appliance in the sagittal, vertical and transverse directions to highlight the key areas for future case selection.

CASE PRESENTATION

A 14-year-old, Indian, female, presented with a chief complaint of protruding upper front teeth. She was in a good health and had no significant medical history.

Clinical examination revealed that she had a Class II Division 1 malocclusion on a moderate Class II skeletal base with an average lower facial height ratio. There was no obvious facial asymmetry. The lips were incompetent, showing 7mm of upper incisors at rest

and 2 mm maxillary gingival display on smiling with a normal upper lip length. The nasolabial angle was obtuse and the labiomento fold was deep (Figure 1).

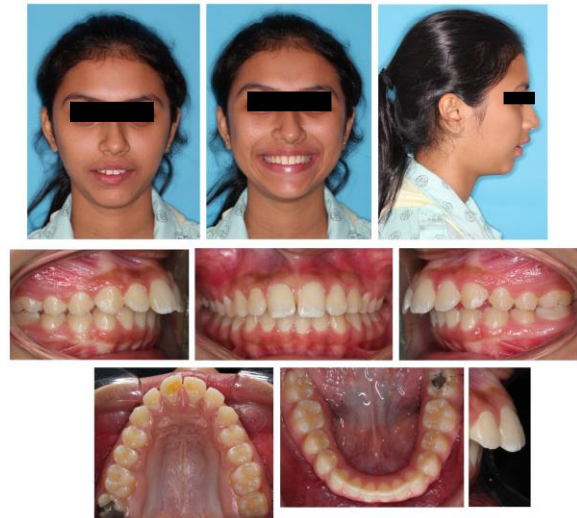

Figure 1. Pre-treatment facial and intraoral photographs

Intraorally, revealed full permanent dentition with 2mm crowding in the upper and well aligned the lower arches. Both the maxilla and mandibular arch shapes were U-shaped. The upper and lower incisors were proclined. On occlusion, the incisor relationship was in a Class II division 1 relationship with an overjet of 10mm. The overbite was increased by 60% and complete to the palate. The curve of Spee measured from the occlusal plane between the distal cusp of the lower second molar to the lower central incisal edge was 2mm. The buccal segment on the right side was in ¾ unit class II and left side was in ½ unit Class II molar relationships. The canine relationships on the right side were full unit Class II and ½ unit Class II on the left side. The upper centerline was coincident with facial midline and lower centre line was 1mm to the right from facial midline.

The pre-treatment panoramic radiograph (Figure 2) showed that the bone level was normal and all teeth were present in the upper and lower arches. All third molars were in the developing stage. Radiopaque restorations were noted on 17 and 37. The lateral cephalometric radiograph (Figure 3) showed that the patient presented with Class II skeletal base with an average maxilla mandibular planes angle, upper and lower incisors were proclined.

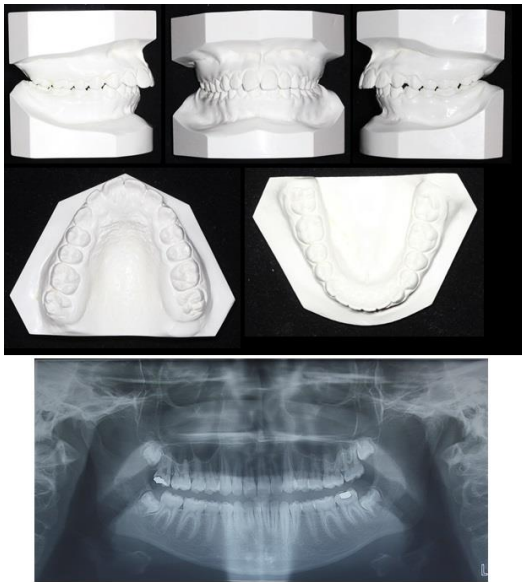


Figure 2. Pre-treatment records showing the study models and panoramic radiograph

The lower lip appeared protrusive from the E-plane by 2.5mm. The cervical vertebral maturation was estimated at cervical stage 5, where the peak in mandibular growth was predicted to have ended at least 1 year before this stage [7].

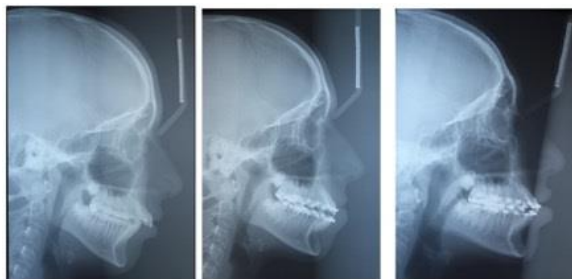

Figure 3. Pre-treatment (left column), mid-treatment after removal of Forsus™ (middle column) and near end of treatment (right column) lateral cephalometric radiographs and tracings.

Treatment Objectives

Our treatment for this patient focused on seven objectives: (1) Secure the optimum oral hygiene before starting the orthodontic treatment; (2) To improve Class II skeletal pattern; (3) Eliminate the dental crowding, level and align the teeth; (4) To achieve a Class I canines and molars relationships bilaterally; (5) Correct overbite and overjet; (6)

Achieve a mutually protective functional occlusion and (7) Retention.

Treatment alternatives

The main problem for this patient was Class II skeletal pattern with increased overjet and overbite. Based on these problems, four options were proposed to the patient's mother.

1. The first option involved a growth modification to take advantage of any remaining residual growth potential despite her age and cervical vertebral maturation stage, in the first phase of treatment. This includes wearing twin block functional appliance for a year and followed by a second phase of treatment comprising upper and lower fixed appliances. This will prolong the treatment and requires great compliance from the patient. The mother doubted her daughter's ability to be compliant to wear the twin block at all times.

2. The second option involved growth modification with fixed functional appliance (Forsus™ Fatigue Resistant Device, 3M Unitek™). This required alignment of the upper and lower teeth followed by the insertion of Forsus™ when reaching 0.019 X 0.025-in stainless steel archwires.

3. The third option involved orthodontic camouflage. This option requires extraction of 14, 24 and 35 with anchorage reinforcement with headgear or mini implant in the upper arch. Extraction of the teeth in the upper arch facilitates the reduction of the overjet but it may worsen the nasolabial angle due to the retraction of upper lip. The patient also refused to have headgear as a part of the treatment.

4. The fourth option involved orthognathic surgery to advance the mandible and improve the facial profile. After the discussion with her father regarding the treatment options, the father did not want her to undergo orthognathic surgery.

After discussing the treatment options with the patient and parents, they agreed with the second option. Written consent was obtained from the parents and the tentative treatment plan included the following: (1) Upper and lower fixed appliances (0.022x0.028-in slot, MBT prescriptions); (2) Placement of Forsus™ Fatigue Resistant Device (3M Unitek™) to advance the mandible (3) Finishing and

detailing; (4) Upper and lower modified Hawley retainers.

Treatment progress

Orthodontic treatment started in April 2014 and finished in October 2016. It took 18 months to finish with a good occlusion. Treatment started with the placement of pre-adjusted edgewise brackets (0.022x0.028-in, MBT prescription) on all the teeth except the second molars.

Upper and lower 0.012-in nickel titanium archwires were placed and treatment progressed until 0.019x0.025-in stainless steel archwires. Initial alignment followed by leveling of the upper and lower arches were achieved in 4 months. Upper and lower 0.019x0.025-in stainless steel archwires were maintained for a month for full torque expression.

On September 2015, Forsus™ Fatigue Resistant Device, 3M Unitek™, 29mm push rod, approximate force was 200g were installed bilaterally on the upper and lower 0.019x0.025-in stainless steel archwires with continuous ligation (0.012-in) from the lower right first molar to the lower left first molar. The archwires were cinched distal to all molars (Figure 4).

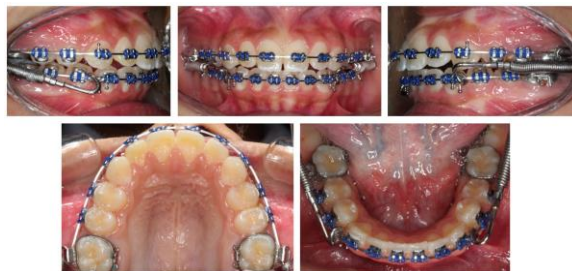

Figure 4. Middle treatment with the installment of Forsus™ on upper and lower 0.019X0.025 -in stainless steel archwires

Two months after the installation of Forsus™ split crimps (1.5mm) were added bilaterally, one on each side, for further activation of the appliance. After 5 months of active Forsus™, overcorrection of molar relationships and overjet were noted. Forsus™ was removed on February 2016 and this followed the regime suggested by Franchi et al. (2011) [5]. Lateral cephalometric radiograph at this stage showed no significant anterior-posterior skeletal changes but dental compensations by retroclination of the upper incisors and proclination of the lower incisors was observed.

The patient was seen after three months to monitor for relapse prior to phase 2 skeletal and dental assessments. It was felt that any extractions would be unfavourable to her facial profile. In particular, the nasolabial angle may appear obtuse if the upper lip support was brought back with further retraction of the upper anterior segment during space closure. Thus, it was decided to proceed with non-extraction approach. At this phase, all the second molars were bonded. Upper and lower 0.012-in nickel titanium archwire were placed and treatment progressed until 0.019x0.025-in stainless steel archwires. Continuous elastic closed powerchains were placed in the upper and lower arches in order to close minor spaces. Finishing and detailing were done in 2 months and brackets were removed in October 2016. The patient was instructed to wear the retainers for 24 hours within 6 months and to continue wearing the retainers at night indefinitely as suggested by Shawsh, 2010 [8].

RESULTS

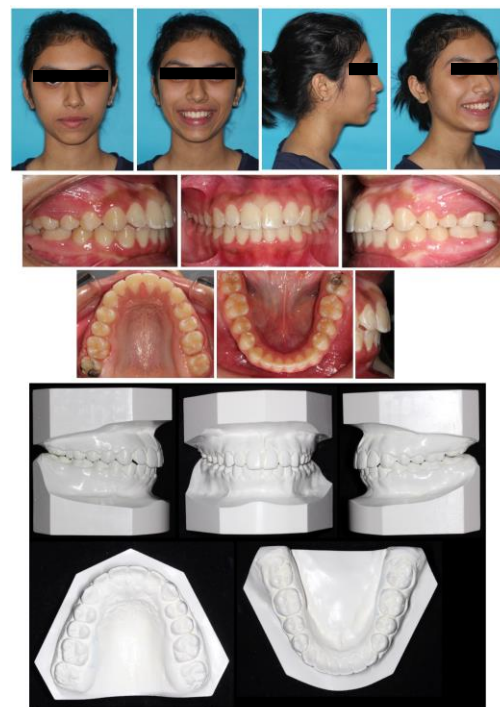

Figure 5. Post-treatment facial and intraoral photographs and study models

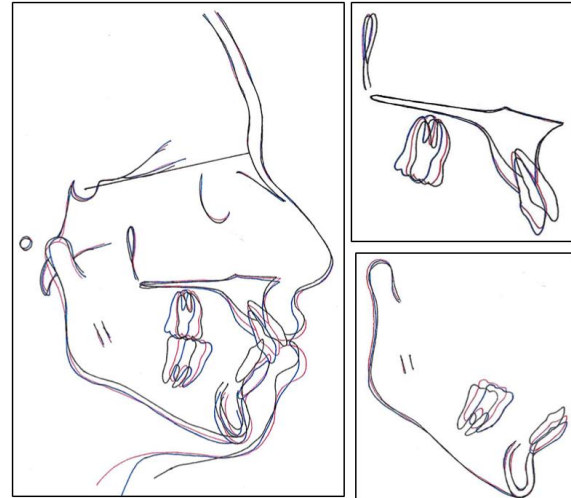
Figures 5 show the final outcome of the case. The active treatment period was 18 months and the treatment objectives were achieved. The facial photographs showed improved profile and smile

aesthetics. The severe overjet and deep overbite were corrected without extractions. At the end of treatment, Class I molars and canines relationships were achieved. The overjet and overbite were also normalized. The post treatment lateral cephalometric radiograph analysis and superimpositions showed there was significant improvement of the facial profile from the general superimposition (Figure 6). The maxillary incisor proclination was improved with a slight retroclination (U1 to MxP, 117°), and the mandibular incisor proclination was slightly increased (IMPA, 101°) to camouflage the skeletal Class II discrepancy. The facial convexity improved with the slight retrusion of the upper lip and increased protrusion of the lower lip.

DISCUSSION

Fixed Functional appliances seem to be effective in improving Class II malocclusion in the short term, although their effects seem to be mainly dentoalveolar rather than skeletal [9]. Fixed functional appliance such as PowerScope and Forsus™ FRD are effective in correcting Class II malocclusion [10]. However, Forsus™ FRD has significantly found to have greater in sagittal skeletal effects [10]. The Forsus™ FRD is a fixed functional appliance, which can bring about mandibular growth and favourable changes in dental and soft tissues while correcting the Class II relationship in patients at or just before the peak phase of pubertal growth. For patients near the end of the pubertal growth period, Forsus™ was deemed to be able to only induce dental compensations [11]. However, in this report, this 14-year-old girl patient who was expected have passed the pubertal growth spurt for at least a year at the first visit as assessed based on the cervical vertebral maturation method [7], showed improved facial profile on top of the dental compensations observed post-treatment. This paper will provide a deduction of the biomechanical effects of this appliance, which has not been previously explained in the literature.

The mandible is postured forward during first installation of the Forsus™ and further activation of 1.5mm using one split crimp. This incremental activation is better when compared to single stage advancement based on studies of Hagg and Rabie [12, 13].



Cephalometric Measurements				
	Pre-treatment	Mid-Treatment	Post-treatment	Difference
Skeletal				
SNA (°)	83°	83°	83°	0°
SNB (°)	76°	76°	76°	0°
ANB (°)	7°	7°	7°	0°
SN-Mx (°)	10°	12°	11°	+1°
FMA (°)	28°	24°	26°	-2°
Dental				
U1 to NA	+6.0mm	+4.0mm	+4.0mm	-2.0mm
U1 to Mx	126°	113°	117°	-9°
L1 to NB	+6.5mm	+10.0mm	+8.0mm	+1.5mm
L1 to MP	97°	107°	101°	+4°
IIA	111°	117°	115°	+4°
Facial				
E-line to UL	-1.5mm	-4.0mm	-2.0mm	-0.5mm
E-line to LL	+2.5mm	+3.0mm	+4.5mm	+2.0mm
LFH ratio	55%	56%	55.9%	+0.9%
<i>U1, maxillary incisor; L1, mandibular incisor; UL, upper lip; LL, lower lip; LFH, lower facial height; Mx, Maxillary Plane; MP, Mandibular plane; IIA, Interincisal Angle</i>				

Figure 6. The overall superimposition, maxillary and mandibular superimpositions with the measurements are also shown. Pre-Treatment (Black), Mid-Treatment (Blue), Post-Treatment (Red)

The neuromuscular tendency to relax the muscles compresses the springs placed between the upper first molars and stainless steel archwire in the lower arch. In turn, Forsus™ create orthodontic forces by the pushing mechanics during force unloading of the compressed springs to result in changes of the dentition in transverse, vertical and sagittal direction [14].

In the sagittal direction, the compression forces created horizontal forces toward the upper first molars and distalised the upper first molars (Figure

7(A)). On the other hand, the moment created in the upper arch and caused the retroclination of the upper incisors. The retroclination of the upper incisors were favourable in this case in order to reduce the overjet and protrusion of the upper lip. In the lower arch (Figure 7(B)), the compression forces created the horizontal forces in the lower arch and mesialised the lower molars. In addition, the moment also created in the lower arch and caused the proclination of the lower incisors. The proclination of the lower incisors also contributed to the reduction of the overjet. Slight proclination of the lower incisors can be favourable for Class II correction but over proclination of the lower incisors may compromise the stability [15].

As Forsus™ requires great anchorage demand in the lower arch to avoid unfavourable effects, clinicians are advised to use mandibular rectangular archwires of full archwire to bracket slot size, the addition of a negative torque also to the archwire in the lower incisor region, tight ligation, rigid tiebacks of the arches, cinchbacks of the wires and negative torque (-6°) bracket of the lower incisors [5]. In this case, such anchorage enhancement technique was incorporated but the lower incisors still proclined. On hindsight, the proclination could have been reduced with incorporation of mini-implant in the lower arch [16].

However, in this case the proclination was within the acceptable limits of 7 degrees [17]. In a vertical direction (Figure 7(C)), the compression forces created vertical forces towards the upper first molars. The direction of force caused the intrusion of the upper molars and the moment created caused extrusion of the upper incisors. Thus the upper occlusal plane rotated in a clockwise direction. In this case, the extrusion of the upper incisors was acceptable and did not compromise the smile aesthetics. Clinician needs to be cautious to treat the Class II division I with a gummy smile using Forsus™ because the extrusion of the upper incisors may worsen the gummy smile. Such Class II division 1 malocclusion with a gummy smile need to be treated with fixed functional appliances, which has a compression force near or towards the estimated center of resistance of the maxilla in order to reduce the clockwise rotation of the maxilla [14]. In the lower arch, the vertical force minimally intruded the lower incisors and simultaneously caused extrusion of the lower molars. The moment created also changed the lower occlusal plane in a clockwise direction.

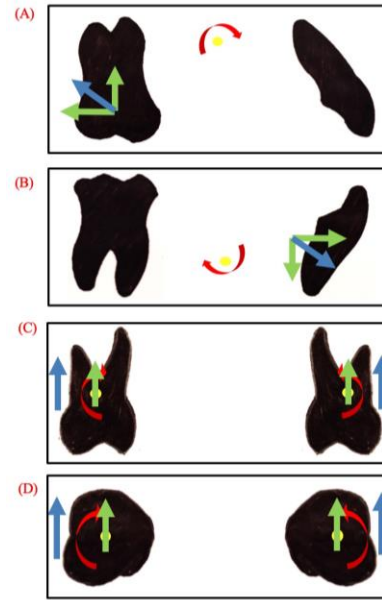


Figure 7. Biomechanics of teeth movement for Forsus™, in the sagittal direction (A and B); vertical direction (C) and transverse direction (D). (A,B) Direct forces from the Forsus™ FRD on the maxilla and mandible (Blue) and are away from the estimated center of resistance, moments created (Red) and changed the occlusal plane. (C) Direct vertical force from the Forsus™ FRD (Blue) to the buccal side of the upper molars and its away from the estimated center of resistance, the moment created (Red) and caused buccal flaring of the upper molars. (D) Direct distal force from the Forsus™ FRD on the buccal side of the upper molars (Blue) and its away from the estimated center of resistance, the moment created (Red) and caused distobuccal rotation of the upper molars

In a transverse direction (Figure 7(D)), the compression forces are concentrated on the buccal surface of the upper molars. These forces flare the upper molars buccally and extrude the palatal cusps. The extrusion of palatal cusp of upper molars leads to the reduction of overbite as happened in this case after removing the Forsus™. The extrusion of the palatal cusp of the upper molars can be prevented by adding transpalatal arch on the upper molars, using the finishing arch wire with rigid 0.019" x 0.025" stainless steel archwire and by applying palatal root torque on the upper first molars. Distal directed forces on the buccal surface of the upper molars give advantage to this case that rotated the upper molar distobuccally (Figure 7(D)). In Figure 8 showed the distobuccal rotation of the upper first molars

facilitated the expansion of the upper arch and simultaneously provide the space for overjet reduction.

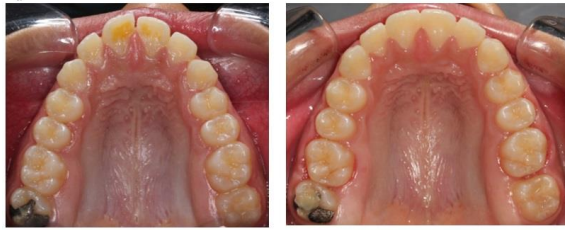

Figure 8. Distobuccal rotation of the upper first molars facilitated the expansion of the upper arch and simultaneously provides the space for overjet reduction

Correction of Class II division I malocclusion required large amount of space of about 14mm in order to reduce the overjet, which is commonly managed with extractions of the upper premolars. In this case, the pre-treatment nasolabial angle did not favour extraction to reduce the overjet as the retracted incisors would displace posteriorly, reducing the lip support and resulting a more obtuse nasolabial angle. By using the Forsus™, space creation was observed through expansion, distalisation and distobuccal rotation of the upper molars as a biomechanical consequence from the use of this appliance. The overjet correction was facilitated by proclination of lower incisors and retroclination of the upper incisors. The facial profile was improved as the lip changes followed the supporting incisors. Overall, a forward and downward displacement of the mandible was observed. This was mainly contributed by a combination of dento-alveolar change and skeletal growth. During Forsus™ treatment as the moment of the forces caused rotation of the occlusal plane, the upper incisors extruded with intrusion of the upper molars. This displaces the mandible downwards as the lower incisors contacts the more extruded upper incisors. Relapse of the Forsus™ treatment caused the occlusal plane to rotate back minimally in an anti-clockwise direction. The mandible follows and displaces in anterior direction as the lower incisors occlude on the more intruded positioned upper incisors. The mandible did not displace back posteriorly because some skeletal growth had occurred as observed on the mandibular superimpositions.

Other changes to the airway were also observed in this case. Mandibular retrognathia has been associated with a decreased oral airway volume, which may be due to posterior positioning of the tongue or a posterior position of the hyoid bone has been associated with reduced oropharyngeal airway volume [18, 19]. Previous study shows that functional appliance therapy in growing patient increases oropharyngeal airway volume, airway dimensions, and anteroposterior hyoid bone position [20]. Meanwhile, functional appliances also used for adults with obstructive sleep apnoea to prevent upper airway collapse during sleeping [21]. In this case, there was enlargement of the airway, which compared in between the pre-treatment and post-treatment lateral cephalometric radiographs (Figure 4). Therefore, Forsus™ FRD may be suggested for obstructive sleep apnoea treatment.

The FRD protocol has led to successful correction of Class II malocclusion in 87.5% of the patients. The protocol had a greater skeletal effect on the maxillary structures by restraining the sagittal advancement of the maxilla. The effects on the mandible were mainly at the dentoalveolar level, with a large amount of mesial movement of the lower incisors and first molars [5].

CONCLUSION

Class II division I adolescent patient with 10mm overjet was successfully treated using Forsus™ FRD. The correction of the overjet and overbite was mainly through dentoalveolar compensation and minimal mandibular growth, which simultaneously improved the patient's profile at the end of treatment

ACKNOWLEDGEMENT

The authors would like to thank all staff at Orthodontic Unit, Klinik Pergigian Cahaya Suria (Sementara) for assistance and contribution to this case report. Special gratitude to the Director General of Health Malaysia and the Principle Director of the Oral Health Division, Ministry of Health Malaysia for permission to have this case report published.

DECLARATION OF INTEREST

The authors report no conflicts of interest. The authors alone are responsible with the content of this article.

REFERENCES

1. McNamara JA Jr. Components of class II malocclusion in children 8-10 years of age. *Angle Orthod.* 1981; 51(3): 177-202.
2. McNamara JA Jr, Brudon WL, Kokich VG. *Orthodontics and dentofacial orthopaedics.* Ann Arbor, Mich: Needham Press, Inc; 2001.
3. Cacciatore G, Alvetro L, Defraia E, Ghislanzoni LT, Franchi L. Active-treatment effects of the Forsus fatigue resistant device during comprehensive Class II correction in growing patients. *Korean J Orthod.* 2014; 44(3): 136-42.
4. 3M, Forsus™ Fatigue Resistant Device Treatment Guide [internet]. St. Paul, Minnesota; 2016. Available from: <https://multimedia.3m.com/mws/media/8230650/forsus-fatigue-resistant-device-treatment-guide.pdf>
5. Franchi L, Alvetro L, Giuntini V, Masucci C, Defraia E, Baccetti T. Effectiveness of comprehensive fixed appliance treatment used with the Forsus Fatigue Resistant Device in Class II patients. *Angle Orthod.* 2011; 81(4): 678-83.
6. Aras A, Ada E, Saracoğlu H, Gezer NS, Aras I. Comparison of treatments with the Forsus fatigue resistant device in relation to skeletal maturity: a cephalometric and magnetic resonance imaging study. *Am J Orthod Dentofacial Orthop.* 2011; 140(5): 616-25.
7. Baccetti T, Franchi L, McNamara JA Jr. The Cervical Vertebral Maturation (CVM) Method for the Assessment of Optimal Treatment Timing in Dentofacial Orthopedics. *Seminars in Orthodontics.* 2005; 11(3): 119-29.
8. Shawesh M, Bhatti B, Usmani T, Mandall N. Hawley retainers full- or part-time? A randomized clinical trial. *Eur J Orthod* 2010; 32(2): 165-70.
9. Zymperdikas VF, Koretsi V, Papageorgiou SN, Papadopoulos MA. Treatment effects of fixed functional appliances in patients with Class II malocclusion: a systematic review and meta-analysis. *Eur J Orthod.* 2016; 38(2): 113-26.
10. Arora V, Sharma R, Chowdhary S. Comparative evaluation of treatment effects between two fixed functional appliances for correction of Class II malocclusion: A single-center, randomized controlled trial. *Angle Orthod.* 2018; 88(3): 259-66.
11. Chaukse A, Jain A, Reddy MSR, Dubey R, John SM, Suma S. Treatment of Skeletal Class II Malocclusion using the Forsus Appliance : A Case Report. *People's Journal of Scientific Research.* 2011; 4(1): 39-42.
12. Du X, Hagg U, Rabie AB, Effects of headgear Herbst and mandibular step-by-step advancement versus conventional Herbst appliance and maximal jumping of the mandible. *Eur J Orthod.* 2002; 24(2): 167-74.
13. Hägg U, Rabie AB, Bendeus M, Wong RW, Wey MC, Du X, Peng J. Condylar growth and mandibular positioning with stepwise vs maximum advancement. *Am J Orthod Dentofacial Orthop.* 2008; 134(4): 525-36.
14. Nand R, *Esthetics and biomechanics in orthodontics.* St. Louis, Missouri: Saunders, an imprint of Elsevier Inc. 2015
15. Ackerman JL, Proffit WR. Soft tissue limitations in orthodontics: treatment planning guidelines. *Angle Orthod.* 1997; 67(5): 327-36.
16. Elkordy SA, Abouelezz AM, Fayed MM, Attia KH, Ishaq RA, Mostafa YA. Three-dimensional effects of the mini-implant-anchored Forsus Fatigue Resistant Device: A randomized controlled trial. *Angle Orthod.* 2016; 86(2): 292-305.
17. Mills JR. The long-term results of the proclination of lower incisors. *Br Dent J.* 1966; 120(8): 355-63.
18. El H, Palomo JM. Airway volume for different dentofacial skeletal patterns. *Am J Orthod Dentofacial Orthop.* 2011; 139(6): e511-21.
19. Muto T, Yamazaki A, Takeda S, A cephalometric evaluation of the pharyngeal airway space in patients with mandibular retrognathia and prognathia, and normal subjects. *Int J Oral Maxillofac Surg.* 2008; 37(3): 228-31.
20. Rizk S, Kulbersh VP, Al-Qawasmi R. Changes in the oropharyngeal airway of Class II patients treated with the mandibular anterior repositioning appliance. *Angle Orthod.* 2016; 86(6): 955-61.
21. Ogutcen-Toller M, Sarac YS, Cakr-Ozkan N, Sarac D, Sakan B. Computerized tomographic evaluation of effects of mandibular anterior repositioning on the upper airway: a pilot study. *J Prosthet Dent.* 2004; 92(2): 184-9.

License Information: This work is licensed under a Creative Commons Attribution