

RECURRENT UROSEPSIS DUE TO NEPHROCOLIC FISTULA IN AN AUTOSOMAL DOMINANT POLYCYSTIC KIDNEY DISEASE

Noor Azmi MNA¹, Muhamad AM¹, Gohar Rahman MN^{1,2}, and Ab Rahim MF³.

¹Department of Surgery, Hospital Pengajar Universiti Sultan Zainal Abidin, 21300 Kuala Nerus, Terengganu, Malaysia

²Faculty of Medicine, Universiti Sultan Zainal Abidin, 20400, Kuala Terengganu, Terengganu, Malaysia

³Department of Surgery, Hospital Sultanah Nur Zahirah, 20400, Kuala Terengganu, Terengganu, Malaysia

Correspondence:

Muhammad Noor Adib Noor Azmi,
Department of Surgery,
Hospital Pengajar Universiti Sultan Zainal Abidin,
21300 Kuala Nerus, Terengganu, Malaysia
Email: nooradib@gmail.com

Abstract

Nephrocolic fistula is an abnormal communication between the kidney and the colon, a rare clinical phenomenon with potentially serious complications. We present a case of a 37-year-old female with autosomal dominant polycystic kidney disease who complained of left lumbar pain, fever and urinary frequency. She had multiple similar presentations for years, refractorily treated for recurrent urinary tract infections. Contrast-enhanced computed tomography abdomen demonstrated bilateral staghorn calculi and perinephric abscesses connected to the descending colon. She eventually required surgical intervention after the failure of medical therapy. Our case highlights the diagnosis and management of nephrocolic fistula.

Keywords: Nephrocolic Fistula, Polycystic Kidney Disease, Staghorn Calculus

Introduction

Fistula between the urinary tract and gastrointestinal tract is uncommon. Nephrocolic fistula was first described by Hippocrates in 460BC and began to be recognized in the 1800s, predominantly due to renal tuberculosis (1). Presently, most fistulas are iatrogenic, which occur after a surgical intervention such as percutaneous nephrostomy, radiofrequency ablation and minimally invasive surgery for stone disease. The fistula often occurs due to renal pathology and is unusual following bowel disease (2, 3).

Case Report

A 37-year-old female complained of dull, aching left lumbar pain for two weeks, associated with fever and increased urinary frequency. She has no haematuria, dysuria, urinary urgency, incontinence, or vomiting. Her bowel habit remained usual, and she did not experience per rectal bleeding. Similar symptoms have repeatedly been recurring for four and a half years. She has been diagnosed with autosomal dominant polycystic kidney disease (ADPKD) and bilateral staghorn calculi, for which she refused intervention. Due to untreated renal diseases, she experienced recurrent urinary tract infections complicated

with bilateral renal abscess formations. The consequence led to multiple hospitalizations, numerous courses of antibiotics and radiological-guided percutaneous drainage of the collections.

Upon presentation, she was dehydrated, tachycardic and feverish. Her abdominal examination revealed tenderness and palpable mass at the left lumbar region with laboratory evidence of marked leucocytosis, raised C-reactive protein, and creatinine levels. Her urinalysis showed microscopic haematuria and bacteriuria, while her urine culture grew *Escherichia coli*. Ultrasonography demonstrated bilateral renal staghorn calculi, multifocal perinephric collections and mild hydronephrosis. After adequate resuscitation, she was subsequently admitted for further diagnostic imaging and management. Contrast-enhanced computed tomography (CECT) abdomen was performed, which revealed enhancing perinephric inflammatory soft tissue reactions and abscess formations at both lumbar areas near the paracolic gutters. Extraluminal left perinephric air pockets were also present, traceable to the adjacent colon. These CECT findings suggest recalcitrant infection of the kidneys and suspicious left nephrocolic fistula (Figures 1 and 2). No right nephrocolic fistula is demonstrable.

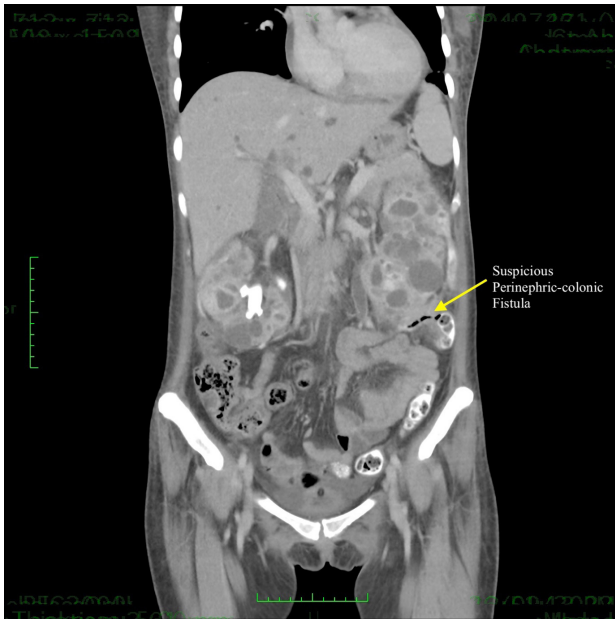

Figure 1: Coronal view CECT abdomen shows a suspicious left perinephric-colonic fistula

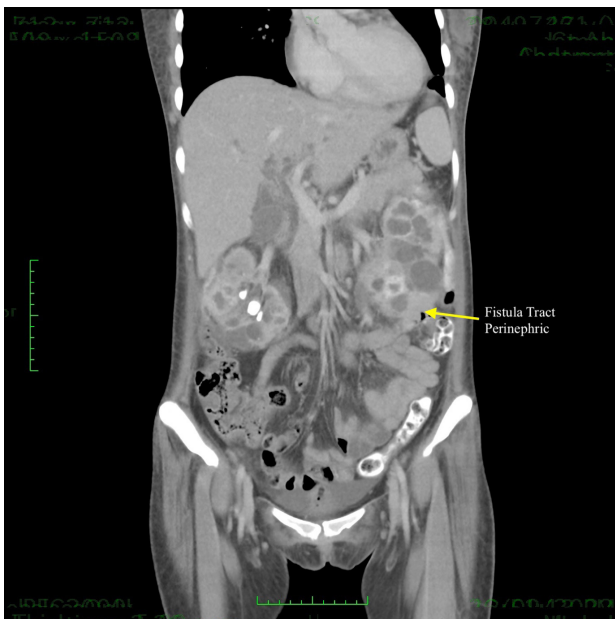


Figure 2: Coronal view CECT abdomen shows the presence of the left fistula tract

A period of a week of conservative management, including close observation, hydration, analgesia, and narrow-spectrum antibiotics, was implemented. However, the patient's condition did not show significant clinical improvement. She was then planned for diversion stoma and abscess drainage, followed by interval hemicolectomy and left nephrectomy.

Discussion

Nephrocolic fistula is a rare occurrence, an anomalous connection between the kidney and the colon, accounting for 58.9% of reno alimentary fistula (4). The fistula may arise from inflammatory processes, iatrogenic procedures, trauma, and malignancy. Chronic inflammatory conditions, such as staghorn calculus, xanthogranulomatous pyelonephritis and renal tuberculosis, are associated with fistula formation (2). Iatrogenic aetiology commonly involves percutaneous nephrostomy insertion, radiofrequency ablation and cryoablation. In cases of malignancy, colon cancer and renal cell carcinoma are usually reported (5).

The fistula abnormally communicates the urinary and gastrointestinal systems, resulting in urine drainage into the gastrointestinal tract and gastrointestinal content into the urinary tract leading to local and systemic manifestations (6). Patients may present with fever, rigour, malaise, lethargy, flank pain and diarrhoea. Urinary symptoms such as dysuria, urinary frequency, pneumaturia and fecaluria raise specific concerns in nephrocolic fistula (3). Our patient, with a background of ADPKD and staghorn calculi, presented with systemic and urinary symptoms in the absence of diarrhoea, alteration of bowel habits or haematochezia; thus, the likely cause of the fistula is pointing towards renal pathology.

Laboratory investigation is nonspecific and potentially demonstrates leucocytosis, raised inflammatory markers, elevated serum creatinine and electrolyte imbalances. Urine analysis may demonstrate the presence of haematuria, bacteriuria and pyuria. As faecal materials enter the urinary tract, urine culture commonly grows bowel commensal organisms (6). This scenario can be seen in our case; her serum creatinine was markedly elevated, urinalysis revealed haematuria, bacteriuria, and urine culture grew *Escherichia coli*, commonly associated with a nephrocolic fistula.

Radiological diagnosis can be made by retrograde pyelography, barium enema or computed tomography. Retrograde pyelography has the advantage of identifying the exact location of the fistula at an area of contrast extravasation. However, it may fail to demonstrate small fistulas and fistulas that are located proximal to an obstructing ureteric calculus or pelviureteric junction (7). Computed tomography helps define the fistula's presence, location, and underlying pathology. Nevertheless, computed tomography may not precisely visualize the fistula tract (8). Parvey et al. (7) recommend both computed tomography and pyelography for accurate fistula diagnosis. In our case, a diagnostic computed tomography revealed the presence of extraluminal air pockets connecting the left kidney to the descending colon, consistent with the diagnosis of nephrocolic fistula. Bilateral kidneys are swollen, enlarged with multiple cysts and forming perinephric abscesses, indicating the origin of the fistula is renal.

The treatment of nephrocolic fistula depends on the aetiology of the fistula, clinical status and renal function. Non-operative management should be considered in stable patients with benign disease, normal renal function and simple fistula. Vanderbrink et al. (9) reported successful non-operative management with symptom resolution by ureteric stent placement. On the contrary, operative management may be required in patients with malignant disease, sepsis, renal failure and complex fistula. The surgery involves nephrectomy, resection of the affected bowel and primary anastomosis if permitted. In some cases, a diverting colostomy may be performed in patients with complex fistula. Wysocki et al. described a successful operative intervention for nephrocolic fistula involving nephrectomy, left hemicolectomy and colostomy (5). Our patient was initially commenced on non-operative management; however, she eventually required surgical intervention due to persistent sepsis and deteriorating renal function.

Conclusion

Nephrocolic fistula is an abnormal, unusual communication between the kidney and the colon. The fistula can alter physiological, biochemical and infectious changes, potentially leading to severe complications. Radiological investigations remain the primary modality for precisely diagnosing the fistula and underlying disease. Although fistulas may heal with non-operative management, surgery is often necessary.

Competing interests

The authors declare that they have no competing interests.

Informed Consent

Informed consent was obtained from the patient for the information to be published.

Financial support

None.

References

1. Bhaskar V, Sinha RJ, Purkait B, Singh V. Renal fistulae: different aetiologies, similar management. *BMJ Case Rep.* 2017; bcr2017219678.
2. Tenkorang S, Omana JP, Bega BS, Sow A, Mellas S, Tazi MF, *et al.* Renocolic fistula secondary to tuberculosis: a case report. *Urol and Androl Open J.* 2017; 1(1):18–21.
3. Pathirana VB, Thilakarathne S. Nephrocolic fistula due to staghorn calculus. *Sri Lanka Journal of Surgery.* 2016; 34(3):14-15.
4. Lin W, Watts K, Aboumohamed A. Renoalimentary fistula: Case report of a renoduodenal fistula and systematic literature review. *Urol Case Rep.* 2018; 18:41-43.
5. Wysocki JD, Joshi V, Eiser J, Gil N. Colo-renal fistula: an unusual cause of hematochezia. *World J Gastrointest Pathophysiol.* 2010; 1(3):106-108.
6. Auld M, Keller A. Renocolic fistula secondary to urothelial carcinoma. *BMJ Case Rep.* 2018; bcr2017223558.
7. Parvey HR, Cochran ST, Payan J, Goldman S, Sandler CM. Renocolic fistulas: complementary roles of computed tomography and direct pyelography. *Abdom Imaging.* 1997; 22(1):96-99.
8. Patel BJ, Mathur AK, Puri N, Jackson CS. A rare case of nephrocolic fistula resulting from radio frequency ablation (RFA) of renal cell carcinoma. *ACG Case Rep J.* 2014; 1(2):93-95.
9. Vanderbrink BA, Rastinehad A, Caplin D, Ost MC, Lobko I, Lee BR. Successful conservative management of colorenal fistula after percutaneous cryoablation of renal-cell carcinoma. *J Endourol.* 2007; 21(7):726-729.